

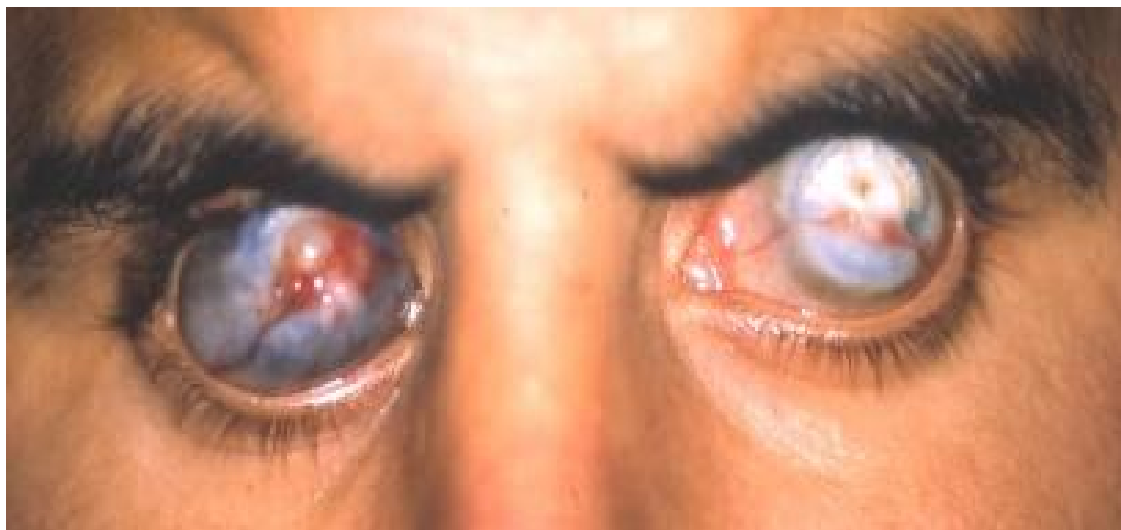

Plate 30: Grottesque looking eyes from advanced congenital glaucoma in a talented university student in the Gaza Strip

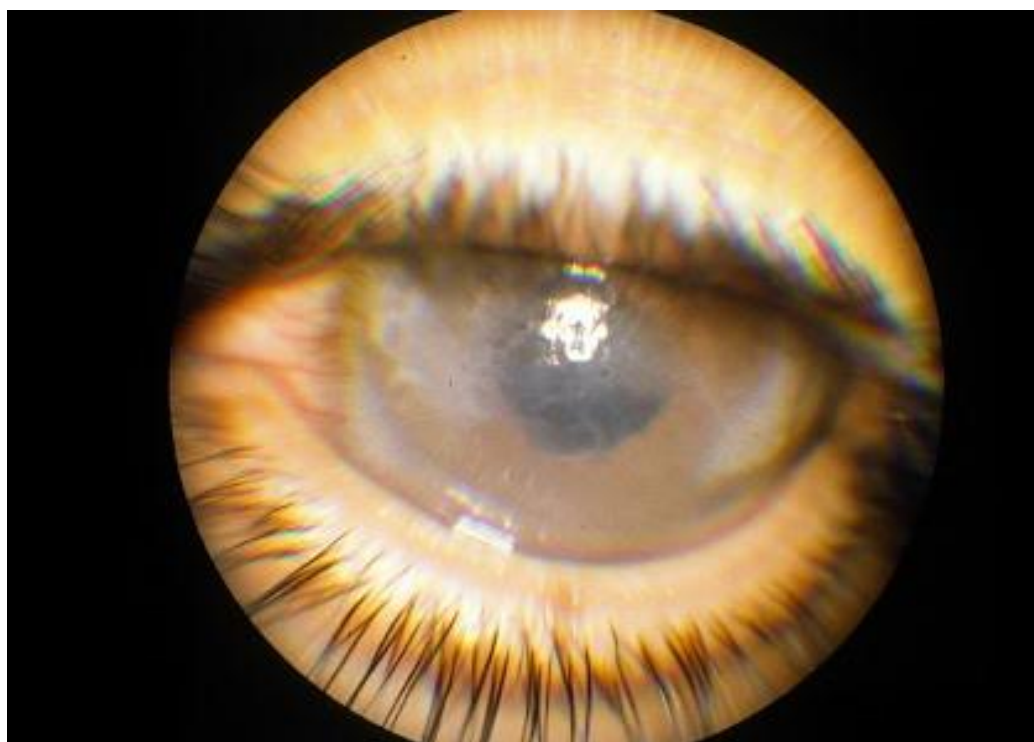


Plate 31: Cornea of child with congenital glaucoma