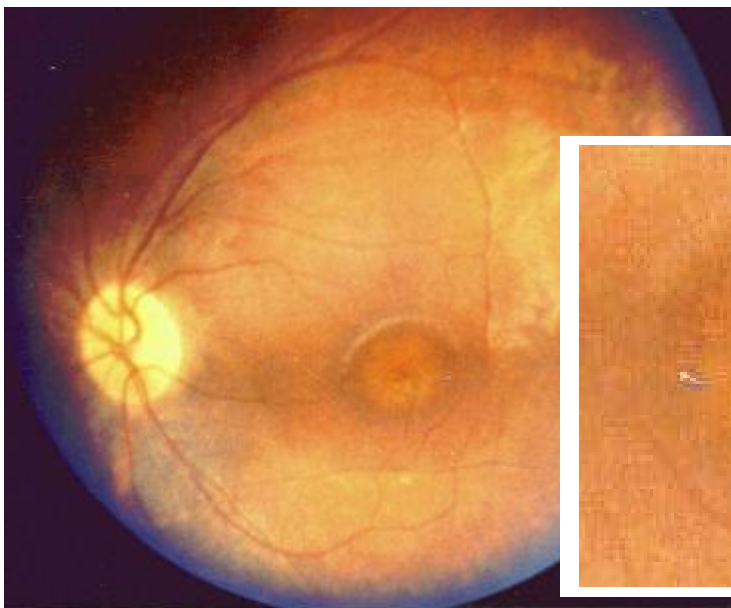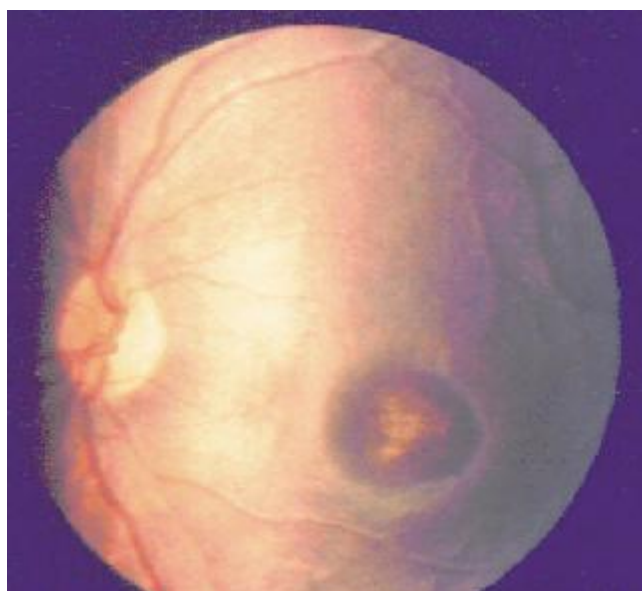
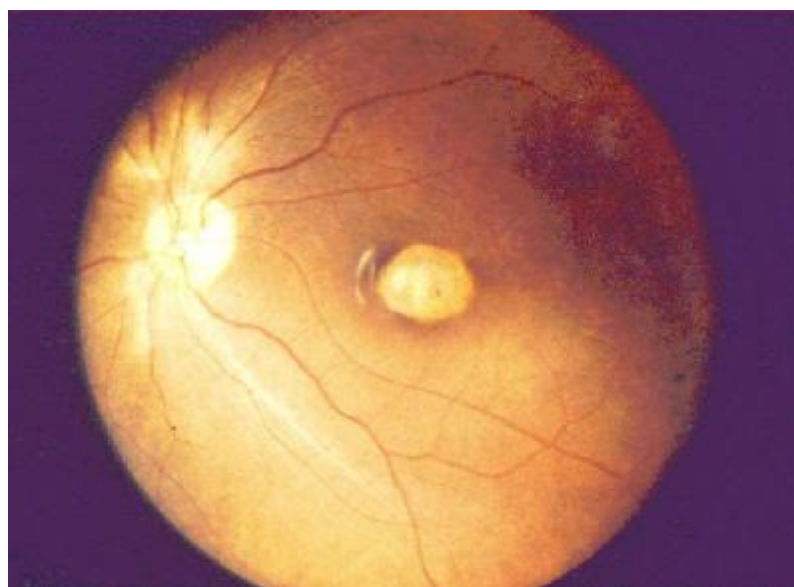


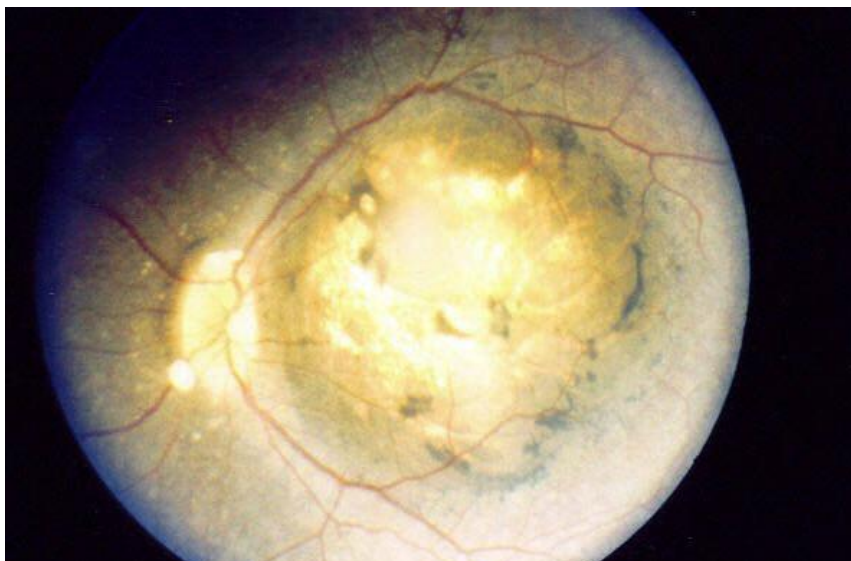**Plate 40a, b: Bull's eye lesion**



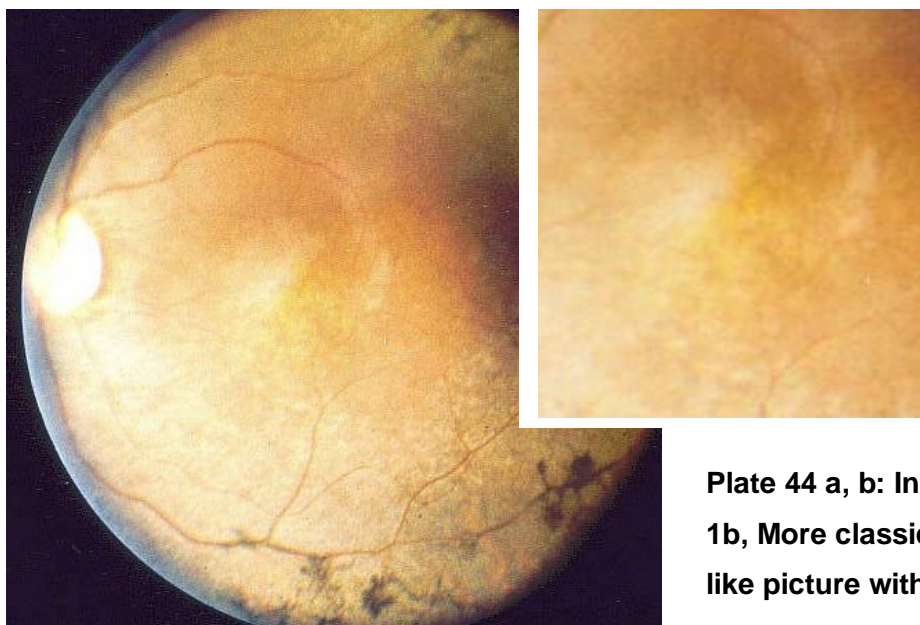
**Plate 41a,b: Macular lesions become more confluent**



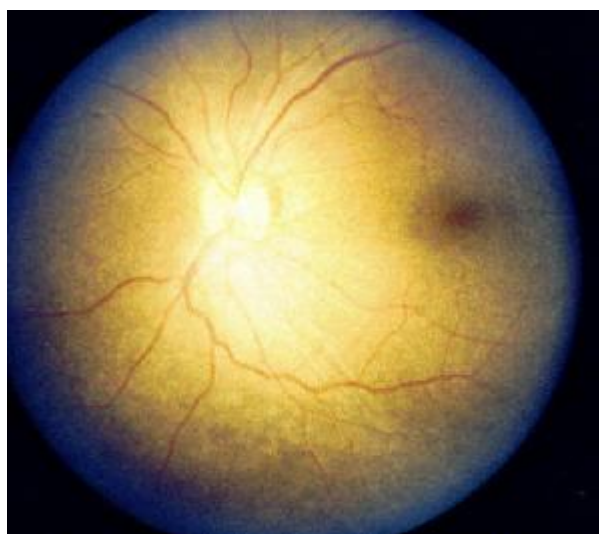**Plate 42: Chorio-retinal atrophy**



**Plate 43: Further excavation leading to posterior staphyloma**



**Plate 44 a, b: In type 1b, More classical RP like picture with**



**Plate 45: Type 2 of the CRD and amelogenesis imperfecta no obvious ophthalmological retinal changes.**