

Plate 50: Congenital hypertrichosis, trichomegaly and a congenital form of cone rod dystrophy (congenital amaurosis of the cone rod) in 2 cousins

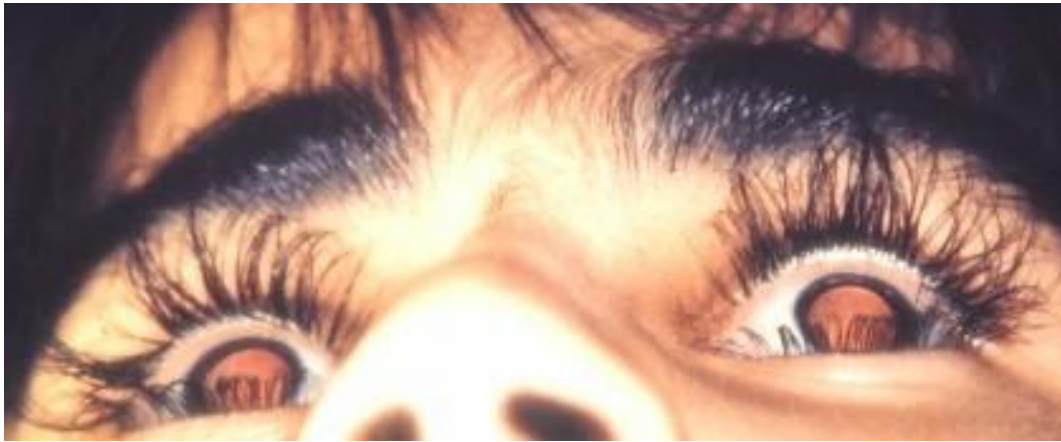

Plate 50: Trichomegaly

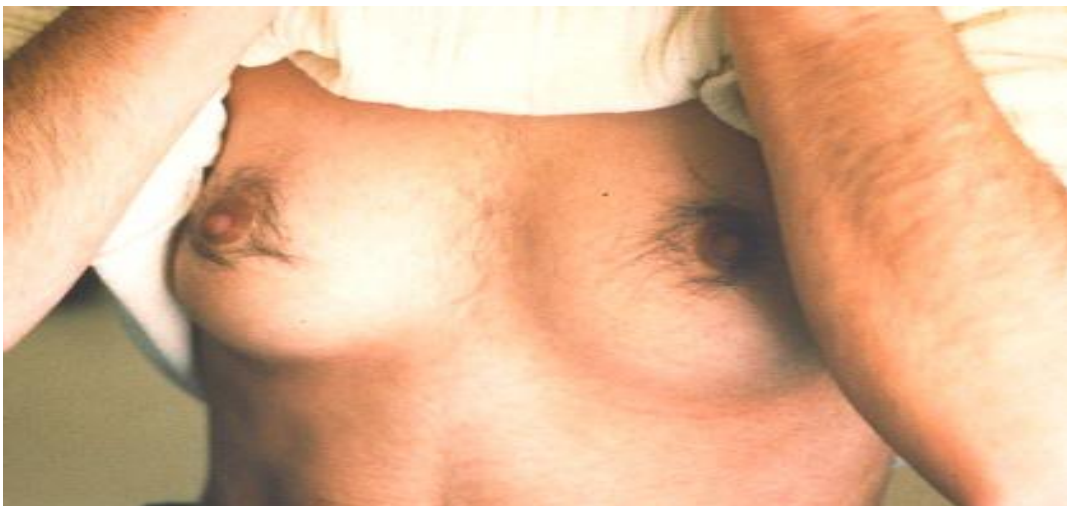

Plate 51: Generalised systemic hypertrichosis

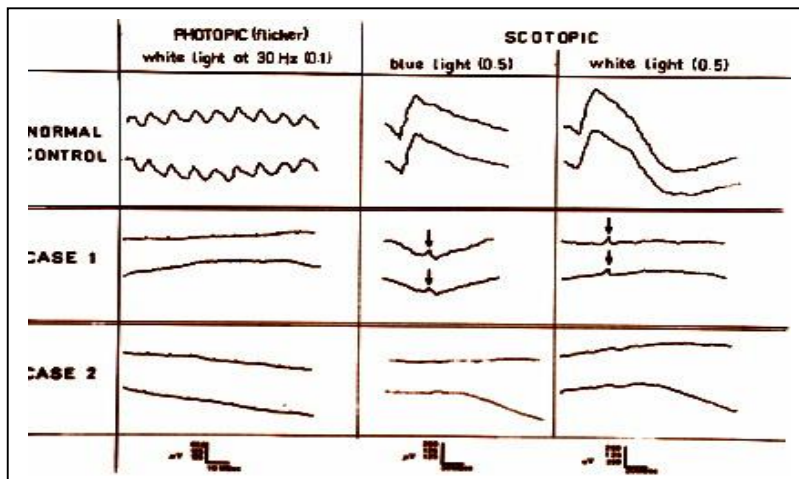


Plate 52: ERG in the above condition:

Top tracing: normal control.

Middle tracing: almost absent rod responses

Bottom tracing:

Extinguished cone responses (lower tracing)